

Low Power Laser Stimulation and UV-Hemotherapy in Treatment Complex of Eye Retinal Ischemia

Elene Mirziashvili, Tamar Sikharulidze, Makrine Mirziashvili, Veta Kuzanova, Manana Koghuashvili

National Eye and Neurological Center, Tbilisi, Georgia

ABSTRACT

Laser stimulation and UV-hemotherapy methods improve eye microcirculation and summary hemodynamics in retinal ischemic diseases: post-traumatic maculodystrophy, post-artefac maculodystrophy, chorioretinal dystrophy. UV-hemotherapy and laser stimulation effect on eye microcirculation results in improvement of eye functional state that involves: widening of vision field, central vision improvement, and significant changes in photo-stress-test and dark adaptation average indexes. Eye microcirculation and hemodynamics improvement, increase of the number of functional capillaries and positive dynamic changes of erythrocytes desegregation have been marked as well. Average conjunctival index has decreased but rheographic index increased two times. Laser-stimulation and UV-chemotherapy positive effect enables its application for treatment in ischemic diseases of eye with complex traditional drug treatment.

KEYWORDS: *laser stimulation, UV-hemotherapy, retinal ischemia, maculodystrophy, conjunctival index, rheographic index*

Retinal ischemic diseases treatment is related with certain difficulties in spite of the modern achievements of medical knowledge. The main goal of the research is to determine low intension laser stimulation and extracorporeal UV hemotherapy effect on eye microcirculation, its hemodynamics and eye functional condition in retinal ischemic diseases especially in maculodystrophy and chorioretinal dystrophy.

UV hemotherapy and low laser stimulation have been performed on 21 patients, among them 10 patients were suffered from post-traumatic maculodystrophy, 5 patients - post-artefac maculodystrophy, and 6 - chorioretinal dystrophy.

10 procedures have been carried out by low intension laser with outcome power 2-10 ml.vat. Each procedure was done by reflection rays made from rotating drum. This event is named indirect irradiation. The laser ray was divided by dispersing lens. In each case 10 procedures have been performed separately and in binocular state. Duration of each procedure was 5 minutes.

8 procedures have been made by UV hemotherapy and the interval between each procedure was 2-3 days. In case of extracorporeal UV hemotherapy blood was irradiated by cubital venipuncture (1-1.5 milliliter blood to 1 kilogram). Blood was irradiated by ultraviolet rays as it goes through special equipment during exfusion and

infusion too. No complications were noted during low power laser stimulation and UV hemotherapy.

Positive morphological and functional changes have been noted in patients for 5-10 days since low laser stimulation and extracorporeal UV hemotherapy was done. The changes include: central vision improvement, expansion of peripheral borders of visual field, and reduction of peripheral and central scotomas and metamorphopsia, the latest one is revealed clearly on Amsler Net.

Photo-stress-test index reduced from 21.1 ± 0.2 to 10.0 ± 1.2 in case of post-traumatic maculodystrophy and from 2.5 ± 0.1 to 11.5 ± 0.14 - post-artefac maculodystrophy, from 2.5 ± 0.5 to 10.0 ± 0.5 - chorioretinal maculodystrophy. Dark adaptive average value reduced from 11.5 ± 0.2 to 5.1 ± 0.1 in case of post-traumatic maculodystrophy, from 9.2 ± 4 to 4.5 ± 0.2 - post-artefac maculodystrophy from 8.2 ± 0.3 to 3.5 ± 0.2 - chorioretinal dystrophy.

Above listed photo-stress test and dark adaptive average indexes display eye functional state improvement. Eye microcirculation and hemodynamics improvement are also noted after low laser stimulation and UV hemotherapy.

Epibulbar conjunctival microphotography method is used to determine eye circulation. Average conjunctival index is estimated by grade system.

| Disease | Average Conjunctival Index before treatment | Average Conjunctival Index after treatment | Average Conjunctival Index reduced gradient |
|-----------------------------------|---|--|---|
| 1. Post-traumatic maculodystrophy | 13.25±0.53 | 6.9±0.19 | 2.1 |
| 2. Post-artefac maculodystrophy | 12.52±0.12 | 6.36±0.24 | 2.3 |
| 3. Chorioretinal maculodystrophy | 16.52±0.35 | 7.11±1.0 | 2.0 |

Tab.1 *Dynamic epibulbar conjunctival indices in retinal ischemic diseases.*

Average conjunctival index = 0.2 ± 0.75 in scales.

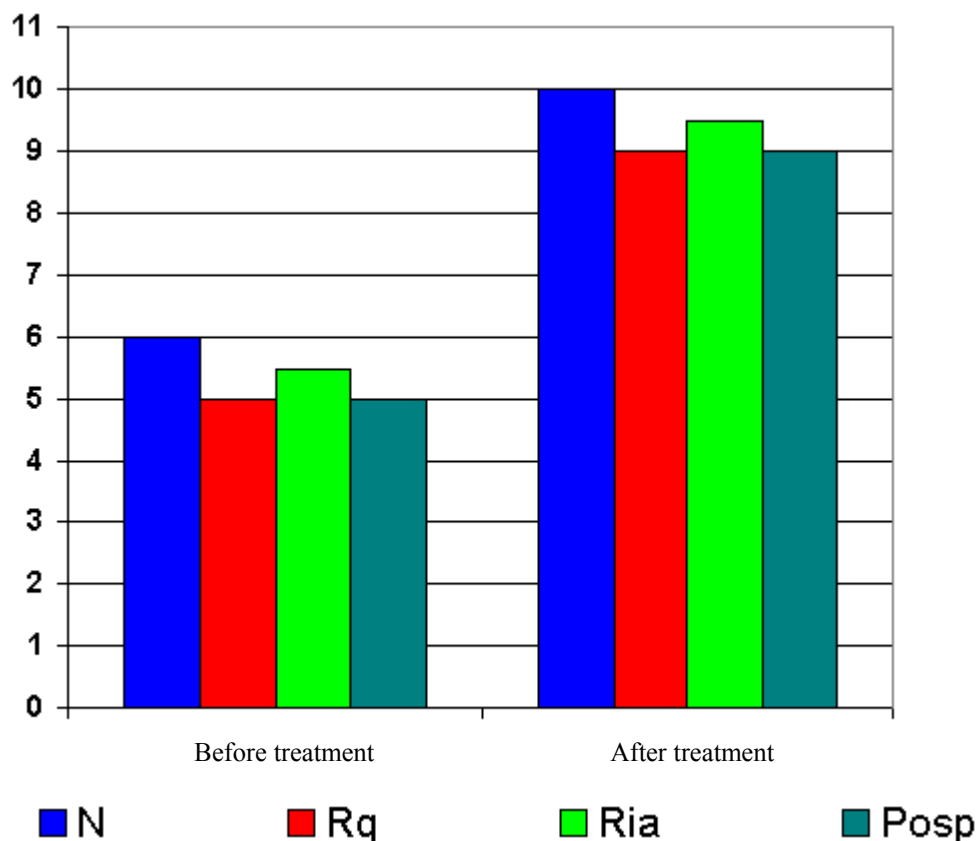


Fig.1 Dynamic rheographic indices before and after treatment.

Patients suffered from post-traumatic, post-artefac maculodystrophy and chorioretinal dystrophy before treatment have high average conjunctival index that is caused by disorder of eye microcirculation. As treatment was made average conjunctival index has reduced two times in all patients that is a direct sign of the significant improvement of eye circulation.

Positive hemodynamic changes of average rheographic index are noted after low laser stimulation and UV hemotherapy. These changes are caused by amelioration of vascular tension, elasticity of vessel walls, its permeability and blood supply. Average rheographic indexes in case of post traumatic and post-artefac maculodystrophy chorioretinal dystrophy have increased two times (Rq, Ria, Rosp increased gradient-2), this fact shows improvement of hemodynamics.

Dynamic rheographic indices presented in Fig.1 indicate of positive laser stimulation and UV hemotherapy effect.

REFERENCES:

1. Shapiro E. S. -Usage of Laser Refractometry To Choose Contact Lens.-Moscow. 1981. Page 84-86.
2. Akhmedova I.B. Medical Laser Refractometry And Its Clinical Study-Moscow. 1983. Page23
3. Markov T.V. Clinical-additional Study In Light-Macular Test-1986 Page 102-104
4. Malaia-Microcirculation In Cardiology-1977 Page 232.
5. Levchenko- Hemodynamics Of Myopic Eye According To Pheophtalmology-1978 Page112-114
6. Bunin A.I-Eye Hemodynamics And Its Application Study-1978. Page112-114
7. Tvaladze M.-Usage Of Retransfusion Blood Irradiated By Ultraviolet Rays In Lung Chronicle Diseases.

The above mentioned findings indicate the increase of functional capillaries number and circulation rate and disaggregation of erythrocytes that results in improvement of microcirculation and hemodynamics.

Use of such methods as low power laser stimulation and UV chemotherapy in case of retinal ischemic diseases ameliorate eye microcirculation, hemodynamics and its functional condition. This is proved by positive dynamic changes of average rheographic and conjunctival indexes.

Low laser stimulation and UV hemotherapy methods with complex traditional treatment assist the improvement of oxygen saturation in tissues, activation of oxidation-reduction processes in cells, disaggregation of erythrocytes and improvement of blood circulation in vessels.

Низкочастотный лазерный стимулятор и UV-гемотерапия в комплексном лечении ишемических болезнях сетчатки глаз

Елене Мирзиашвили, Тамар Сихарулидзе, Макрине Мирзиашвили, Вета Кузанова, Манана Козуашвили

Национальный центр офтальмологии и неврологии, Грузия

Р Е З Ю М Е

С применением лазерной стимуляции и UV-гемотерапии проведены курсы комплексного лечения 21 больных с ишемическими болезнями сетчатки глаз: 10 – с пост-травматической макулодистрофии, 5 – с пост-артефак макулодистрофии и 6 – с хориоретинальной дистрофии. Полученные результаты показали улучшения функционального состояния глаз: расширение полевого зрения, улучшение центрального зрения, значительные изменения в фото-стресс-тесте и в средних показателях индекса адаптации в темноте. Также, отмечены улучшение микроциркуляции и гемодинамики клетчатки глаз: увеличение числа функциональных капилляров и положительная динамика изменения десегрегации эритроцитов. Средние показатели конъюнктивального индекса уменьшились, а реографического индекса увеличились почти в два раза. Результаты подчеркивают положительный эффект применения лазерной стимуляции и UV-гемотерапии в комплексном лечении ишемических болезнях сетчатки глаз.

КЛЮЧЕВЫЕ СЛОВА: лазерная стимуляция, UV-гемотерапия, ишемия сетчатки, макулодистрофия, конъюнктивальный индекс, реографический индекс